

PHILOSOPHICAL TRANSACTIONS.

IV. *The Blood-corpuscle considered in its different Phases of Development in the Animal Series. Memoir I.—Vertebrata. By T. WHARTON JONES, F.R.S., Lecturer on Anatomy, Physiology and Pathology, at the Charing-Cross Hospital, &c.*

Received February 27,—Read June 19, 1845.

PART I.

THE mode in which I purpose to treat this part of my subject, is to trace the blood-corpuscle in its different phases of development in the vertebrate series, from the lower to the higher classes.

I commence therefore with the blood-corpuscle of the Skate, taken as an example of the lowest class.

Examination of the Blood-corpuses of the Skate.

1. There are in the blood of the Skate two kinds of corpuscles, which at first view, under the microscope, especially attract the notice of the observer: the one kind is without colour, but appears dark in consequence of refracting the light strongly, is of a roundish form, and about $\frac{1}{1800}$ th of an inch in diameter, or even larger; the other kind, which is more numerous, is of a red colour and oval form, and measures about $\frac{1}{1100}$ th of an inch long, by $\frac{1}{1700}$ th of an inch broad (figs. 1, 2 a, 3, and 7.).

2. *Structure of the first-mentioned kind of Corpuscle.*—The first-mentioned kind of corpuscle is composed of an agglomeration of granules surrounded by a cell-membrane. The granules are clear and strongly refract the light. They measure about $\frac{1}{20,000}$ th of an inch in diameter, but it is to be remarked, that they may at one time appear separate, and at another time more or less fused together, as if they had been granules of quicksilver.

3. In consequence of the structure, so far as it has been described, of the corpuscle under consideration, I propose to designate it by the name of *granule blood-cell*.

4. On one side of this granule blood-cell, a clear spot may sometimes be seen, indicating the place of a nucleus (fig. 1.).

MDCCCXLVI.

K

5. By the action of water, the cell-wall becomes distended so that it is enlarged in diameter; at the same time the aggregation of the granules becomes less close and their appearance of fusion less; sometimes I have seen the granules suddenly collapse and flatten under the action of water, as if they had been small vesicles bursting (fig. 2 *a.*).

6. By the action of acetic acid much diluted, the granulous mass is dissolved, but the cell-wall is left, and in its interior there is now distinctly seen a cellæform nucleus, about $\frac{1}{4300}$ th of an inch in diameter (fig. 2 *b.*). I have watched individual cells during the action of the acid on them, and have seen one granule disappearing after another in the most beautiful and striking manner, until the nucleus came into view.

7. I have above spoken of the granule blood-cell as being of a roundish form: as the blood of the Skate subjected to examination was obtained from the blood-vessels of the viscera already removed from the animal, I cannot say what form the granule blood-cell would present in blood drawn from the animal during life and forthwith examined. But in some examples of the blood which I examined, and which was obtained at a time which could not have been long after the death of the animal, the granule-cells at first presented most remarkable changes of shape and other phenomena immediately to be described, which after a time ceased to be presented, the cells settling into a round form.

8. As the changes of shape and other phenomena to which I refer, resembled appearances presented by what we shall find to be the corresponding corpuscle in the blood of the Frog and of other animals, drawn during life, I am disposed to believe that they will also be found presented by the granule-cells of blood actually drawn from the living Skate.

9. My attention was first attracted to the phenomena by observing a granule-cell with the granules apparently escaping from it as if burst (fig. 3.). But the cell soon appearing again with all the granules collected together, I was led to watch, and soon perceived that the appearance of granules escaping, as if from a burst cell, was owing to this:—the transparent and colourless cell-wall bulged out on one side, leaving the granules still agglomerated and holding together, but this only for a short time; for soon single granules were seen to separate and burst out from the rest, and to enter the hitherto empty compartment produced by the bulging out of the cell-wall. The regular manner in which this sometimes took place was remarkable. I have actually seen the granules enter the compartment by one side and circulate along the bulging cell-wall to the other side, until the whole compartment became filled with granules. This having occurred the bulging began to subside, but was succeeded by a bulging of another part of the cell-wall, into which again a flow of granules took place; and so on all round the cell.

10. *Structure of the Red Oval Corpuscle.*—This is readily recognised to be an oval-shaped cell, with a nucleus round or oval, and with red-coloured contents. It thus resembles the well-known red corpuscle of the blood of the Frog, in structure as well

as in general appearance ; the only difference being that its nucleus is cellæform, whereas that of the red corpuscle of the Frog is, as we shall find, rather solid-looking. The red oval corpuscle of the blood of the Skate under consideration, I propose to name *nucleated blood-cell*, in contradistinction to the granule-cell, which, though also nucleated, is not in general discovered to be so until after the solution of the granules by acetic acid, and which in consequence of its being filled with granules is otherwise well designated granule blood-cell*.

11. Besides the two kinds of cells which I have now described in the blood of the Skate, there are others which, on account of their paleness, do not at first attract so much attention, but which it is of the greatest importance particularly to notice.

12. One kind (fig. 4 *a.*) has the characters of the granule-cell, only the granular contents are very fine and do not so strongly refract the light, hence its paleness. This pale granule-cell I consider an advanced stage of the dark-looking granule-cell. This latter I will call the *coarsely granular stage*, the former the *finely granular stage* of granule-cell.

13. Another kind of the corpuscles referred to, has essentially the same structure as the red nucleated blood-cell above described, being a cell containing in its interior a cellæform nucleus (fig. 5 *a.*) ; the only difference is that both cell and nucleus are circular (the former about $\frac{1}{1800}$ th of an inch in diameter, the latter about $\frac{1}{3000}$ th), and that the cell is either destitute of colour or but slightly tinged red.

14. That this circular nucleated cell is an early stage of the oval red nucleated cell is shown by the circumstance, that besides it there are cells having the same structure but more or less oval-shaped, and still either altogether uncoloured, or slightly tinged red (fig. 6.), which evidently form a transition to the oval red nucleated blood-cell.

15. Two stages of the nucleated blood-cell may thus be recognised, an *uncoloured* and a *coloured stage*.

16. The description now given of the nucleated blood-cell of the Skate in the uncoloured stage, and a comparison of figures 5 *a.* and 2 *b.* will show that it resembles the granule blood-cell after its granules have been dissolved by the action of acetic acid ; the only difference being that in the former the cellæform nucleus is larger and more developed.

17. This resemblance, and the circumstance that corpuscles occur in which the cellæform nucleus is large, but still surrounded by a few granules (fig. 4 *b.* ; see also the corresponding corpuscle in the Lamprey, represented in fig. 2.), and which may be viewed as a transition from the granule to the nucleated cell, go to prove that the nucleated blood-cells are developed from the granule blood-cells—are, in fact, the granule blood-cells with the cellæform nucleus developed, at the expense of the granules which have disappeared.

* The name "granule-cell" I have borrowed from Professor VOGEL of Gottingen, who first employed it to designate a form of cell which is developed in inflammatory exudations.

18. The conclusion to be drawn from what has now been said in regard to the relationship between the granule blood-cell and the nucleated blood-cell is, that they are to be viewed as two different phases of development of the same body, the granule-cell being the *first phase of development*, the nucleated cell the *second phase of development*. Each phase of development again comprehends two principal stages: the phase of granule-cell, *a coarsely and finely granular stage*; the phase of nucleated cell, *an uncoloured and a coloured stage*.

19. In the osseous fishes which I have examined for the purpose, the blood-corpuscle in its phases and stages of development is essentially the same as in the Skate. In the Lamprey also, which is a cartilaginous fish lower in the scale than the Skate, the blood-corpuscle in its phases and stages of development is the same, with the exception that the nucleated cell in its coloured stage is circular, as well as that in the uncoloured stage (figs. 4 a, 3.)*.

20. It is worthy of remark, however, that there is a fish, the lowest of the lowest division, in which the blood is perfectly colourless, viz. *Branchiostoma lubricum*, COSTA, *Amphioxus lanceolatus*, YARRELL†. The corpuscles of the blood of this fish have not been examined, but there can be little doubt that some of them are the same as the granule blood-cells of the Skate or Lamprey, and others the same as the nucleated blood-cells in their uncoloured stage. If this be so, the blood of *Branchiostoma lubricum* would differ from that of other fishes, merely in the absence of nucleated cells in the coloured stage. It is quite possible, however, although the blood appears perfectly colourless, that nucleated cells in the very commencement of the coloured stage may exist.

21. From Fishes I now proceed to Reptiles, and as an example of a Reptile I take the Frog, in which to examine the blood-corpuscle.

Examination of the Blood-corpuscles of the Frog, and a comparison of them with those of the Skate.

22. In the blood of the Frog, as in that of the Skate, the following kinds of corpuscles are to be recognised:—granule-cells and nucleated cells; the former in coarsely and finely granular stages, the latter in uncoloured and coloured stages.

23. What are usually spoken of under the names of “lymph,” or “colourless” corpuscles, are the granule-cell in both its stages, and the nucleated cell in its uncoloured stage. The relation of these corpuscles to the lymph will be considered in Part Second of this paper; here I view them as corpuscles existing in the blood, and therefore as blood-corpuscles: blood-corpuscles, moreover, differing from each other

* Professor RUDOLPH WAGNER was the first to point out the circular form of the red blood-corpuscle of the Lamprey, but he does not appear to have noticed the existence of a nucleus.

† MÜLLER, Mikroskopische Untersuchungen über der Bau und die Lebenserscheinungen des *Branchiostoma lubricum*, COSTA, *Amphioxus lanceolatus*, YARRELL. Auszug aus dem Monatsbericht der königl. Preuss. Akademie der Wissenschaften zu Berlin, Dec. 1841.

in their degree of development, and not to be confounded together under one specific name or epithet, whether "lymph" or "colourless."

24. *Granule Blood-cells.*—The corpuscle in the blood of the Frog, clearly identical with the granule blood-cell of the Skate in the coarsely granular stage, is roundish, and contains clear granules strongly refracting the light, like those of the same cell in the blood of the Skate, only not so large (fig. 1 *a.*). These granules are usually collected in greater number to one side. The cell itself I have seen, on carefully watching it in blood drawn from the living animal, exhibiting changes of shape with movements of the granules, such as have been above described in regard to the granule-cell of the Skate (par. 7 *et seq.*).

25. By the addition of water this granule blood-cell becomes somewhat distended, and if then *very much diluted* acetic acid, or rather to express myself more correctly, water very slightly acidulated with acetic acid, be added, the granules are dissolved and a cellæform nucleus about $\frac{1}{3500}$ th of an inch in diameter comes into view (fig. 1 *b.*). If stronger acetic acid is added, instead of one such nucleus, the appearance of two or more smaller ones lying close together is apt to be presented.

26. The granule blood-cell in the finely granular stage of the Frog, when by the action of water it has become distended, presents itself of a regular circular form with a diameter usually about $\frac{1}{1200}$ th or $\frac{1}{1300}$ th of an inch, but sometimes greater, sometimes less (fig. 2 *b.*). It contains an indistinctly granular matter which does not refract the light much, and therefore it appears very pale.

27. Before being acted on by water, the cell under consideration usually presents itself of an irregular shape with processes shooting out from it (fig. 2 *a.*). After the blood is drawn, it rapidly undergoes the change to this shape, which, it is to be observed, is somewhat analogous to the change of shape which the coarsely granulous blood-cell presents.

28. When by the action of water the cell has been distended, a cellæform nucleus is sometimes already visible in the interior through the finely granular contents (fig. 2 *b.*), but by the action of acetic acid one is always brought distinctly into view. The diameter of this cellæform nucleus in the state of distention in which it is seen, may be put down at about $\frac{1}{2200}$ th of an inch.

29. Instead of one cellæform nucleus of this size, an appearance of two, three, or even four smaller ones, may be brought out (fig. 2 *c.*), and this even more readily than in the case of the coarsely granulous cell (par. 25.). I am satisfied, however, that this is in both cases merely an appearance produced by the shrivelling together of the walls of the single cellæform nucleus in consequence of the action of the acetic acid.

30. It is proper to observe, that I have come to this conclusion only after having particularly tested the point by repeated, careful, prolonged and varied observations. Nor is the determination of the point of small moment, as on the appearance of a multiple nucleus which I have thus shown to be artificially produced, and on a similar, but I believe equally artificially produced appearance of a multiple nucleus in the

pus-corpusele, a particular view has been founded as to the first formation of the nucleus, and indeed as to cell development generally. This subject I hope to consider on another occasion.

31. To return. I have observed that when the blood was treated with water first, so as to distend fully the cells in question, and then the acetic acid added in a very dilute state, never more than a single large cellæform nucleus came into view; whereas if the acid was added a little less diluted, and before the distending action of the water had been allowed to have its full effect on the cell, very generally an appearance of two or more small cellæform nuclei came into view. Though these nuclei have sometimes appeared as if detached from each other, they have been usually in contact, and I have been able to trace the contour of the original single cellæform nucleus from the one small body to the other.

32. By the action of water alone I have, indeed, sometimes seen, in those cells in which the nucleus is already visible through the finely granulous contents, an appearance as if the nucleus were subdivided into smaller, but very generally this has not been the case.

33. The distortion of shape, produced by external agencies, which I have now described as giving a false idea of the real structure of the cellæform nucleus of the granule-cell of the Frog, has its analogue in the now well-known distortion which the primitive tubules of nervous substance so readily undergo.

34. *Nucleated Blood-cells—Uncoloured stage.*—In the blood of the Frog, besides the granule-cells just described, there are seen uncoloured but distinct and well-defined corpuscles, round or oval, finely granulated, and refracting the light to a certain degree, and about $\frac{1}{3200}$ th of an inch in diameter.

35. These corpuscles are apt to be confounded with the granule-cells, and appear to have been sometimes taken for free nuclei. They are nuclei but not free*, being surrounded by a cell-wall, which, without a good microscope and good light, is readily overlooked on account of its great paleness. This very pale cell, with distinct nucleus, which is the nucleated blood-cell in the uncoloured stage, may be circular (fig. 4.), or oval (fig. 5.), and of a size approaching that of the red corpuscle, or nucleated cell in the coloured stage.

36. Sometimes the pale cell-wall so closely embraces the nucleus as not to be distinguishable at all until distended and brought out by the addition of water, when it appears as represented in fig. 3.

37. This nucleated blood-cell in the uncoloured stage of the Frog is very similar to that of the Skate, the principal or indeed only difference being that its nucleus has become solid-looking and condensed, so that it has little of the cellæform appearance which the nucleus of the corresponding cell in the Skate presents.

38. *Nucleated Blood-cell—Coloured stage.*—This is the well-known red oval corpuscle of the blood of the Frog (fig. 6.). It is the counterpart of the red oval cor-

* There may sometimes be seen free nuclei (par. 101.), *Note*.

puscle, or nucleated blood-cell in the coloured stage of the Skate, as above mentioned. The principal difference between the cells in question in the two animals, is in the character and appearance of the nucleus; whilst in the red cell of the Skate, the nucleus, though more or less oval, still retains its cellæform appearance; in that of the Frog it is still more solid-looking and condensed than it was in the nucleated cell in the uncoloured stage, and at last acquires the appearance as if consolidated by fusion into a small oval-shaped homogeneous mass.

39. The development of the red oval corpuscle or nucleated cell in the coloured stage from the nucleated cell in the uncoloured stage, can be readily understood to take place by the latter secreting into its interior colouring matter, becoming at the same time enlarged, and all this in the manner above explained in regard to the red nucleated cell of the Skate.

40. But as to the development of the nucleated cell in the uncoloured stage from the phase of granule-cell, this appears to take place in the following manner:—The cellæform nucleus of the granule-cell becomes developed into the solid-looking nucleus at the expense of the granules which disappear. As this takes place, the cell-wall contracts around the nucleus, becoming thicker and stronger, and by and by only becomes distended again by the accumulation of contents, as above described in the case of the Skate (par. 17.)*.

41. The blood-corpuscle of the Frog in its phases of development, thus resembles in all essential respects the blood-corpuscle of the Skate.

42. It would be supererogatory to institute a formal examination and comparison of the blood-corpuscle of any other oviparous vertebrate animal, but for the sake of what comparison may be desired, I have given figures of the blood-corpuscle of a bird in its different phases of development.

43. I now come to consider the blood-corpuscle of Man and the Mammifera in its different phases of development.

In the first place, it is to be observed that, as in the early embryonic state of the Mammifera, the red corpuscles of the blood are most of them very different from the red corpuscles of the blood in a more advanced stage of intra-uterine life as well as after birth, I will, in treating this subdivision of my subject, first examine the blood-corpuscles of the early embryo of a mammiferous animal, comparing them at the same time with those of the oviparous Vertebrata; and then I will examine the corpuscles of the fully-formed blood of Man and the Mammifera, comparing them with those of the early embryonic blood of the same class, and also with those of the blood of the oviparous Vertebrata.

* The probability of such a mode of development of the red corpuscle of the blood of the Frog from the "lymph" or "colourless" corpuscle (granule-cell), has been already well-advocated by Professor H. NASSE and also by Dr. BALY in his translation of MÜLLER'S Physiology.

Examination of the Blood-corpuscles of an Embryo Ox, about $1\frac{1}{4}$ inch in length, and a comparison of them with those of Oviparous Vertebrate Animals.

44. The blood of this embryo presented the following kinds of corpuscles:—

1. Granule-cells in coarsely granular and finely granular stages.
2. Nucleated cells in uncoloured and coloured stages.
3. Small red corpuscles similar to those of the fully-formed blood of the animal.

45. *Granule-cells.*—Some of these contained pretty large and well-defined granules and refracted the light strongly,—coarsely granular stage (fig. 1.); others presented less defined granules, and refracting the light less, appeared very delicate and pale,—finely granular stage. Fig. 3 represents one of these cells with the cellæform nucleus already visible through the finely granular contents; this may be viewed as a transition to the phase of nucleated cell, whilst fig. 2 represents a granule-cell intermediate between the coarsely and finely granular stages.

46. The size of these granule-cells was from about $\frac{1}{1460}$ th to about $\frac{1}{1825}$ th of an inch in diameter.

47. *Nucleated Cells—Uncoloured stage.*—In these, as in the corresponding cells of the blood of the Frog, the nucleus, quite cellæform however, was very distinct, presenting a contrast with the scarcely visible cell-wall (fig. 4.). In some, as above described in the Frog (par. 36.), the cell-wall closely embraced the cellæform nucleus, so that this at first appeared free, until by the addition of water the extremely pale cell-wall was brought out. Often the distention of the cell-wall took place on one side only, presenting the appearance delineated in figure 5. In some again the cell-wall was not only distended but pretty distinct, and even slightly reddish (fig. 6.).

48. The size of the cellæform nucleus was from $\frac{1}{4860}$ th to $\frac{1}{3650}$ th of an inch in diameter, and the cell itself in those in which it was distended from about $\frac{1}{2430}$ th to $\frac{1}{1460}$ th of an inch in diameter.

49. *Nucleated Cells—Coloured stage.*—Most of these were circular (fig. 7 a.), but some were oval (fig. 8.). The circular measured about $\frac{1}{1930}$ th of an inch in diameter. The oval measured about $\frac{1}{1460}$ th in the long diameter and about $\frac{1}{2125}$ th of an inch in the short diameter. The cellæform nucleus, when not at first evident, was brought distinctly into view by the addition of very dilute acetic acid, or even of water merely. It was circular, and measured from about $\frac{1}{4170}$ th to about $\frac{1}{3650}$ th of an inch in diameter (fig. 7 b.).

50. As to the *small red corpuscles similar to those of the fully-formed blood* (fig. 9.), they were rather larger than in the grown animal. They closely resembled the cellæform nuclei of the nucleated cells, only they were red, whilst the latter were uncoloured. There were some free corpuscles however uncoloured which resembled the cellæform nuclei of the nucleated cells, and also the small red corpuscles *minus* their colour.

51. Not having yet had an opportunity of examining the blood on its first appearance in the mammiferous embryo, I do not know if small red corpuscles already

exist then, but in embryos a little further advanced than that, the blood of which is at present under consideration, I found the number of small red corpuscles greater,—that of the nucleated red corpuscles less; and in foetuses still farther advanced, the well-marked nucleated red corpuscles had altogether given place to the small red corpuscles.

52. Putting the small red corpuscles out of view, the blood of the early mammiferous embryo here examined resembles the blood of the oviparous Vertebrata in presenting, besides granule-cells, nucleated cells both in uncoloured and coloured stages.

53. In regard to the red nucleated cells it is to be remarked, that the circular ones were the most numerous, and as they are identical in appearance, size and structure, with the red corpuscles of the blood of the Lamprey, with the exception that their cellæform nuclei are larger, the blood of the mammiferous embryo might be compared to a mixture of the blood of the Lamprey, with a small quantity from a skate or frog to supply the few oval red nucleated cells, and a small quantity from a calf to supply the small red corpuscles.

54. I now proceed to examine the corpuscles of the fully-formed blood of Man and the Mammifera, and to compare them with those of the blood of the early mammiferous embryo and of oviparous vertebrate animals.

Examination of the Corpuscles of the fully-formed Blood of Man and the Mammifera, and a comparison of them with those of the Blood of the early Mammiferous Embryo and of Oviparous Vertebrate Animals.

55. In this examination and comparison, I will inquire,—first, if there be any corpuscles corresponding to granule-cells; secondly, if any corresponding to nucleated cells; and lastly, if the “red corpuscles” are found not to correspond to nucleated cells in the coloured stage, I will inquire into what they correspond to.

56. Here I omit, as I did above in the case of the blood-corpuscles of the Frog, the use of the terms “lymph” and “colourless” corpuscles as altogether destitute of definite meaning, purposing in the second part of this paper to consider, likewise in the case of Man and the Mammifera, what relationship exists between the corpuscles of their blood, usually confounded together under these names, and the corpuscles of their lymph.

57. *Granule Blood-cells.*—The corpuscles in the blood of Man and the Mammifera corresponding to the granule-cells of the blood of the animals above considered, are certain of those commonly spoken of under the name of “lymph” or “colourless” corpuscles—not all, as will be shown below, par. 66.

58. Both coarsely and finely granular stages of the granule-cell may be recognised. In human blood they in general become speedily collapsed after the blood is drawn, and some, especially those in the finely granular stage, may be seen on careful inspection shooting out processes (fig. 2 *a.*) like the same cells in the blood of the

Frog (par. 27.). In this state they look as if they had burst, but such is not the case in general.

59. By the addition of water, the collapsed granule-cells become distended and their appearance is thus distinctly brought out. Fig. 1 *a.* represents the human granule-cell in its coarsely granular stage thus distended; the contained granules, it will be observed, are minute, and on attentive observation they are seen to be in active molecular motion. Fig. 2 *b.* represents the finely granular stage of granule-cell of human blood, distended by water.

60. The granule-cell of human blood is sometimes seen to present, though not very strikingly, a clear spot indicating, as I think, the place of the nucleus, similar to that above represented in the case of the granule-cell of the Skate.

61. When distended by the action of water the human granule blood-cell is about $\frac{1}{2400}$ th of an inch in diameter.

62. Fig. 3 *a.* represents the granule-cell, coarsely granular stage, and fig. 4 the granule-cell in its finely granular stage of the blood of the Horse. Figs. 5 *a.* and 6 represent the coarsely and finely granular stages of the granule-cell of the blood of the Elephant. It will be observed that the diameter of these cells is somewhat greater than that of the granule-cell of human blood, but the principal difference is the size of the contained granules in the coarsely granular stage. Whilst in the granule-cell, coarsely granular stage, of the Horse the granules may be estimated in round numbers at about $\frac{1}{15,000}$ th of an inch in diameter, those in the same cell of the Elephant are about $\frac{1}{20,000}$ th, and those in the human granule blood-cell about $\frac{1}{25,000}$ th.

63. If, after the granule blood-cell has been distended by the action of water, very dilute acetic acid be added, the contained granules are dissolved, and a cellæform nucleus brought into view. Fig. 1 *b.* represents a human granule-cell so acted on; fig. 3 *b.* a granule blood-cell of the Horse similarly acted on; and fig. 5 *b.* a granule blood-cell of the Elephant in the process of being acted on by acetic acid. This last drawing was made before the granules were all dissolved, but when the cellæform nucleus was already distinctly in view. In the case of the cells here represented, as indeed in the case of many others, I watched the progress of the action of the acetic acid on the granules and the coming into view of the cellæform nucleus.

64. If, before the addition of the acid, the granule-cell has not been distended by the action of water, and if the acid has not been much diluted, instead of one cellæform nucleus of the size represented, and which in the human granule-cell may be about $\frac{1}{3650}$ th of an inch in diameter, but larger in the Elephant and smaller in the Horse, an appearance of several smaller ones variously aggregated may be brought out. This, however, in opposition to what is generally believed, and in opposition to what I myself once believed, I can affirm most positively is merely an appearance artificially produced by the corrugating action of the acid on the walls of the single cellæform nucleus, altogether in the manner above shown to be the case with the cellæform nucleus in the corresponding cells of the blood of the Frog.

65. *Nucleated Blood-cells—Uncoloured stage.*—In human blood to which water has been added, besides the distended granule-cells, cells of the same size may be seen, not containing granules, but presenting most distinctly a single cellæform nucleus (fig. 7.). Such cells resemble the granule-cell deprived of its granules by the action of acetic acid. Moreover, it will be observed that they are essentially similar to the nucleated blood-cells in the uncoloured stage of the blood of the mammiferous embryo and of the oviparous vertebrate animals. In their mode of development from granule-cells, as indicated by the occurrence of cells in transition stages (fig. 10.) as well as in their structure, they are in fact clearly identical. I recognise them therefore as the corpuscles in human blood *in the phase of nucleated cell, uncoloured stage.*

66. In consequence of the collapsed state into which they fall immediately on the blood being drawn (fig. 8.), these uncoloured nucleated cells of human blood are scarcely to be distinguished from the collapsed granule-cells (fig. 2 a.) until after distention by water. They are usually confounded with them under the same name of “lymph” or “colourless” corpuscle.

67. In the blood of the mammiferous animals which I have yet examined in reference to the point under consideration, viz. the Horse, Elephant, Paco, Sheep, Goat and Rabbit, uncoloured nucleated cells likewise exist, those of the blood of one animal resembling those of the blood of another, and all resembling those of human blood in all essential particulars of structure. What difference there is consists in the size of the cell, but especially in the size of the cellæform nucleus, as may be seen by comparing the figures 9 and 11 of the nucleated blood-cells of the Elephant and Goat for example; the cellæform nucleus of the former being about $\frac{1}{3000}$ th, that of the latter only about $\frac{1}{6000}$ th of an inch in diameter.

68. *Nucleated Blood-cells—Coloured stage.*—In the blood of Man unacted on by reagents I have not yet observed such corpuscles, but in the blood of other mammifera which I have examined, especially in the blood of the Horse and Elephant, I have observed them. Fig. 13 represents one of several such corpuscles observed in the blood of the Horse which had been drawn from the animal for a day or two, but to which no water or other reagent had been added either before or during the examination. The transparent and colourless circumferential ring, the optical expression of the transparent and colourless cell-wall doubled on itself, formed a striking contrast with the red-coloured interior of the cell, as did also the uncoloured circumference of the cellæform nucleus. This nucleated cell differed from the nucleated cell in the uncoloured stage in not being collapsed. The one delineated was not plumply distended, but others were. Fig. 14 represents a coloured nucleated cell from the blood of the Elephant more fully distended.

69. Fig. 15 a. represents a nucleated cell slightly tinged red, which was observed in human blood, but only after the addition of water; fig. 15 b. represents a still more slightly tinged nucleated cell, observed likewise after the addition of water, in the blood of the Horse, and figs. 16 and 17 represent similar ones from the blood of the

Sheep and Paco. These may be looked on as transitions from the uncoloured to the coloured stage of nucleated cell, such as have been above referred to in the blood of the early mammiferous embryo and in that of the oviparous Vertebrata.

70. Having thus demonstrated, besides granule-cells both in coarsely and finely granular stages, nucleated cells, both in uncoloured and coloured stages, in the fully-formed blood of the Mammifera, as well as in their early embryonic blood, though in much smaller number and of a much less deep colour as regards the cells in the coloured stage*, I now come to inquire into the nature of the well-known "red corpuscles" of the fully-formed blood of the Mammifera.

71. "*Red Corpuscle*" of the fully-formed blood of Man and the Mammifera.—In consequence of similarity of colour, it has been generally taken for granted that this is the exact analogue of the "red corpuscle" or coloured nucleated blood-cell of the oviparous Vertebrata. Physiologists have accordingly supposed that it should contain a nucleus; but though unsuccessful in the attempt to demonstrate one, they have not altogether ceased to believe in the existence of an exact analogy between it and the "red corpuscle" or coloured nucleated blood-cell of the oviparous Vertebrata; they have rather had recourse to conjecture to account for the absence of a nucleus.

72. In reference to this point, the red nucleated cell of the blood of the early mammiferous embryo has been especially appealed to; it being considered by Mr. GULLIVER, and I think correctly, as the exact analogue of the "red corpuscle" or coloured nucleated blood-cell of the oviparous Vertebrata. But to take it for granted that the "red corpuscle" of the fully-formed blood of the Mammifera is the exact analogue of the red nucleated cell of their early embryonic blood, is not more warranted than to take it for granted that the "red corpuscle" of the fully-formed blood of the Mammifera is the exact analogue of the red nucleated blood-cell of the oviparous Vertebrata.

73. Under the impression however that the "red corpuscle" of the fully-formed blood of Man and the Mammifera is the exact analogue of the red nucleated cell of the blood of the early mammiferous embryo, Mr. GULLIVER endeavours to account for the absence of a nucleus in the former by supposing that it disappears at an early period of intra-uterine life. This apology for the absence of a nucleus in the "red corpuscle" of the fully-formed blood of Man and the Mammifera, would have had weight if the "red corpuscle" had been an object persistent throughout life like a limb or an eye, but as it is an object constantly disappearing and being regenerated, we should expect, if it were really a nucleated cell originally, to meet with it in a stage when it does contain a nucleus.

* It is proper to mention that an appearance simulating that presented by the circumferential doubling of the cell-wall and by the slightly coloured interior of the nucleated cell, coloured stage, of fully-formed mammiferous blood, may be produced by the diffraction of the light around any corpuscle. As the diffracted shadows referred to however are always concentric with the corpuscle, error from this source may with certainty be avoided by the unpractised observer in all those cases at least, in which the cellæform nucleus is situated eccentrically within the cell.

74. Professors H. NASSE*, SCHULTZ† and HENLE‡, who appear to have observed the nucleated cell of the fully-formed mammiferous blood both in its uncoloured and coloured stages as above described, have supposed it to be the “red corpuscle” in such a stage. But its larger size (compare figs. 13 and 20, 14 and 23, 11 and 24) seems to forbid such a supposition. Supposing however that this objection could be waived, still it is nothing but unsupported conjecture to say that the nucleated cell and the “red corpuscle” are *exactly* the same body in different stages of development.

75. On the other hand, there is a chain of evidence which appears to me to point forcibly to a different view of the nature of the “red corpuscle” of the fully-formed blood of Man and the Mammifera, whilst by implication it as forcibly forbids the supposition that the nucleated cell and “red corpuscle” are exactly the same body—the latter the same as the former, only *minus* its nucleus, and with an increase of colour.

76. The view of the nature of the “red corpuscle” of the fully-formed blood of Man and the Mammifera to which I refer is this: the “red corpuscle” of the fully-formed blood of Man and the Mammifera is the cellæform nucleus of the nucleated cell set free by the bursting of this cell itself, and become filled and red by the secretion of globuline and colouring matter into its interior; and the chain of evidence which appears to me so forcibly to point to it is the following:—

77. 1st. *Correspondence in Size between the Cellæform Nucleus of the Nucleated Cell and the “Red Corpuscle.”*—Whilst, as we have seen, there is a marked difference in size between the nucleated cell and the “red corpuscle” of the same blood, there is on the contrary a striking correspondence in size between the cellæform nucleus of the nucleated cell and the “red corpuscle.” A glance at the figures will show this. In human blood, in which the “red corpuscle” is large, the cellæform nucleus of the nucleated cell is large. In the blood of the Horse, in which the “red corpuscle” is less, the cellæform nucleus of the nucleated cell is also less. Again, in Sheep’s blood, in which the “red corpuscle” is still less, the cellæform nucleus of the nucleated cell is still less.

78. These facts, and the fact already pointed out by Mr. GULLIVER, that the nucleus of the red nucleated corpuscle of the blood of the early mammiferous embryo is about the same size as the “red corpuscles” in the same blood, which are similar to those of the fully-formed blood of the animal, were sufficient to draw my attention to the correspondence in size between the cellæform nucleus of the nucleated cell and the “red corpuscle,” but not sufficient to satisfy me that it was more than a coincidence. I therefore became desirous of testing further the correspondence; and for this purpose it occurred to me that the blood of the Elephant (in which the “red corpuscles” are larger than those of any mammiferous animal, as Mr. GULLIVER has

* Article “Lympe,” WAGNER’s Handwörterbuch. The blood referred to by NASSE was that of pregnant women especially.

† MÜLLER’s Archiv, 1839, p. 252. The blood examined was that of the Elephant.

‡ Allgemeine Anatomie, p. 444, Pl. IV. fig. 1 E. c. The blood referred to appears to be human blood.

shown) and the blood of the Napu Musk Deer (in which, according to the same authority, the red corpuscles are smaller than those of any other mammiferous animal) would be well-adapted.

79. Accordingly I made application to the Council of the Zoological Society for leave to obtain a minute quantity of blood from the animals I have mentioned. With this request the Council of the Society readily complied*, so far as regards the Elephant, but could not as regards the Musk Deer, there being at present no specimen in their menagerie. As a substitute for the blood of the Musk Deer I have had recourse to that of the Goat, as distinguished for very small "red corpuscles."

80. The result of my examination of the blood of the Elephant is, that the cellæform nucleus of the nucleated cell is larger than that of any other animal the blood of which I have examined, and that it presents a remarkable and exact correspondence in size with the "red corpuscle" of the same animal. (See figs. 9 and 23.)

81. The result of my examination of the blood of the Goat is, that the cellæform nucleus of the nucleated cell is smaller than that of any other animal the blood of which I have examined. As to its correspondence in size with the red corpuscles, this does not at first view appear so complete as in the preceding instances; the large majority of "red corpuscles" being smaller than the cellæform nucleus of the nucleated cell. There are, however, some "red corpuscles"† which exactly correspond in size with the cellæform nucleus of the nucleated cell (see figs. 11 and 24), and these have all the characters of the early stage. (See below, par. 86.)

82. Notwithstanding this slight discrepancy in the blood of the Goat, which moreover is rather apparent than real, I believe that it will be admitted as a general proposition, that there is a close and constant correspondence in size between the cellæform nucleus of the nucleated cell and the "red corpuscle" of the same blood.

83. 2nd. *Correspondence in Form between the Cellæform Nucleus of the Nucleated Cell and the "Red Corpuscle."*—In the blood of the animals which I had hitherto examined, I had found the cellæform nucleus of the nucleated cell circular, and therefore so far corresponding in shape with the "red corpuscle;" but not considering this conclusive as to the existence of an essential relation in respect of form, it occurred to me that the point might be tested by a reference to the blood of the Camel tribe, in which the red corpuscles are of an oval shape.

84. Accordingly, availing myself of the liberal permission granted me by the Council of the Zoological Society, I procured a small quantity of the blood of the Paco, and subjected the cellæform nucleus of its nucleated cells to a comparison with its "red corpuscles." The result was that in the nucleated cells generally the cellæform

* I most gladly seize the present opportunity to express my sense of the obligation thus conferred on me by the Council of the Zoological Society.

† The disproportion in size between the nucleated cell and the "red corpuscle" of the blood of the Goat is still greater than that between the nucleated cell and the "red corpuscle" of the blood of the other mammiferous animals which I have examined, and therefore still more strongly forbids the supposition that the nucleated cell and the "red corpuscle" are the same body.

nucleus was circular (fig. 12.). In a few nucleated cells indeed the cellæform nucleus was of a somewhat oval shape (fig. 17.), but this did not seem to be more than what I had occasionally observed in the blood of those Mammifera, in which the "red corpuscles" are circular.

85. My reference to the blood of the Paco thus appeared to decide against an essential correspondence in form between the cellæform nucleus of the nucleated cell and the "red corpuscle." A little further study of the blood of the Paco however soon cleared away this apparent difficulty, and showed me a state of things more corroborative of my view regarding the nature of the "red corpuscle," and in much closer correspondence with analogy perhaps than would have been that which I supposed possible. I discovered, in fact, corpuscles in different stages of transition, from the circular form similar to that of the cellæform nucleus within the nucleated cell, to the oval form of the perfect "red corpuscle;" and I also discovered that in these different stages of transition in respect of form there are different degrees of coloration (figs. 26, 27, 28, 29, 30.).

86. I had already observed progressive degrees of coloration in the circular "red corpuscles" of the Mammifera generally. Thus, in the blood of the Horse, for example, I had observed corpuscles (fig. 19.) similar on the one hand to the "red corpuscle" (fig. 20.) but uncoloured, and on the other to the cellæform nucleus of the nucleated cell (fig. 15.), and this in all respects. Such corpuscles I was disposed to regard as cellæform nuclei recently set free from the nucleated cells, but not yet reddened by the secretion of colouring matter into their interior. Again, I had observed corpuscles similar to those just mentioned but presenting a red tinge in the middle, the circumference untinged appearing like a transparent and colourless ring (fig. 21.); but the combination of progressive stages of coloration of the "red corpuscle" with its progressive changes of form in the blood of the Paco is peculiarly interesting.

87. The transition from the circular to the oval shape presented by the "red corpuscle" of the Paco, is analogous to that which we have seen presented by the red nucleated cell of the oviparous Vertebrata. It is also worthy of remark, that like the latter the oval red corpuscle of the Paco is reduced to a circular form by the action of water (fig. 31.). The progressive degrees of coloration are also analogous to what are presented by the nucleated cells of the blood of the oviparous Vertebrata. But it is curious to observe, that whilst among the Mammifera the attainment of the oval form by the "red corpuscle" is exceptional, among the oviparous Vertebrata the attainment of the oval form by the red nucleated cell is the rule.

88. But to return to the bearing of the facts I have now related on the question before us. They show that originally the "red corpuscles*" of the Paco are of a circular form like the "red corpuscles" of other mammifera, but that whilst the latter remain circular, the former gradually acquire an oval shape. From this it follows that the circular form of the cellæform nucleus of the nucleated cell of the blood of the Paco, so far from being an objection to the view of the nature of the "red corpuscle"

* In their original circular form they are as yet uncoloured.

of the Mammifera which I am advocating, is just what should be according to it. In short, I consider the "red corpuscle" of the Paco, in its circular form and as yet uncoloured state, to be, like the similar corpuscles referred to in par. 86, cellæform nuclei but recently set free from the nucleated cell.

89. 3rd. *Correspondence in Structure between the Cellæform Nucleus of the Nucleated Cell and the "Red Corpuscle."*—The cellæform nucleus of the nucleated cell is a simple cell or vesicle without nucleus or nucleolus, and as such exactly resembles the "red corpuscle" minus its red coloured contents. Indeed, when by the action of water the "red corpuscle" is deprived of its red coloured contents without being rendered indistinct, the resemblance in respect of structure is very striking, as indicated by the lumen and transparent circumferential ring—the optical expression of the double contour of the wall of the collapsed cell or vesicle.

90. As already said, "red corpuscles" may occur uncoloured or with the lumen only red, the circumferential ring just referred to remaining transparent and colourless. This indicates that the colouring matter is contained in the interior of the cell or vesicle. In its perfect state however the "red corpuscle" appears red at the circumference also, owing, apparently, to its wall being impregnated with colouring matter.

91. The absence of anything like a nucleus in the "red corpuscle" of the fully-formed blood of the Mammifera is in correspondence with the absence of anything of the kind in the cellæform nucleus of the nucleated cell. The appearance of dots, as if of nucleoli, occasionally seen in the latter, I consider to be mere corrugations, similar to those which give rise to the mulberry appearance which the red corpuscle is so prone to assume.

92. Before admitting the correspondence in size, form and structure, between the cellæform nucleus of the nucleated cell and the "red corpuscle" of the blood of the Mammifera which I have now demonstrated, as evidence in favour of their identity, it will be proper to inquire if there be any points of difference between them sufficient to constitute evidence to the contrary effect.

93. *Points of Difference between the Cellæform Nucleus of the Nucleated Cell and the "Red Corpuscle."*—1st. The cellæform nucleus of the nucleated cell refracts the light more than the "red corpuscle." 2nd. The cellæform nucleus is not affected by water or acetic acid like the "red corpuscles"—the former being by the action of these reagents rendered more distinct, the latter rendered indistinct. These circumstances indicate a chemical difference between the cellæform nucleus and the "red corpuscle," and if a satisfactory explanation of them could not be offered they would constitute a powerful argument against my view. But I believe the following explanation will remove the difficulty.

94. *The objection against the identity of the Cellæform Nucleus and "Red Corpuscle" which might be founded on the different modes in which they refract light, and are affected by Chemical Reagents, explained away.*—The differences mentioned are striking enough between the cellæform nucleus and the "red corpuscle" in its perfect state; but if we take the "red corpuscle" in the stage when, as I have already described,

it is as yet uncoloured or presents colour only in its interior, then we find but little difference between it and the cellæform nucleus of the nucleated cell, either in the mode in which it refracts light, or in which it is affected by water or acetic acid. Even when fully red, the "red corpuscles" are not all equally affected by the action of water or acetic acid; some being always seen which resist to a greater or less degree the action of these reagents. Such corpuscles have been considered to be advanced formations, they appear to me on the contrary to be recent.

95. From this it appears that the "red corpuscle" in its advanced stage does not differ, in the respects under consideration, more from the cellæform nucleus of the nucleated cell than it does from what is undoubtedly itself in an early stage. The differences mentioned therefore argue nothing against the identity of the cellæform nucleus and the "red corpuscle."

96. There being thus no evidence to the contrary effect, the correspondence in size, form and structure, between the cellæform nucleus of the nucleated cell and the "red corpuscle" of the blood of the Mammifera, which I have now demonstrated, will I believe be admitted to constitute pretty forcible evidence as to their identity. Whether any additional evidence can be adduced will be seen in the sequel*, par. 106.

97. If the view of the origin and nature of the "red corpuscle" of the fully-formed blood of Man and the Mammifera which I have now given be correct, this "red corpuscle" must be considered as a third phase of development of the blood-corpuscle, and of which there occur uncoloured and coloured stages. This third phase I propose to call the phase of *free cellæform nucleus*†.

98. The different phases and stages of development of the blood-corpuscle in the Vertebrata, such as I have now traced them, may be summed up thus:—In all the vertebrate animals examined, oviparous, and mammiferous, we find blood-corpuscles in what I call the first phase of development, or phase of granule-cell, this presenting

* The view of the nature of the "red corpuscle" of the fully-formed blood of Man and the Mammifera which I have now propounded, must not be confounded with VALENTIN'S view that the blood-corpuscles are nuclei, seeing that he makes no distinction between the blood-corpuscles of the oviparous Vertebrata and those of the Mammifera in this respect. Considering them as analogous to each other, he views them equally as nuclei. The nuclei of the "red corpuscles" of the oviparous Vertebrata he considers to be nucleoli. According to my view, on the contrary, the "red corpuscles" of the blood of Man and the Mammifera are not the analogues of the "red corpuscles" of the blood of the oviparous Vertebrata, but strictly the analogues of their nuclei, as also of the nuclei of the nucleated "red corpuscles" of the blood of the early mammiferous embryo.

Messrs. GULLIVER and REMAK have made observations on the blood of the Horse, from which they have inferred that the "red corpuscles" are formed within the "colourless ones," and that they become free by solution of the latter. GULLIVER however represents colourless corpuscles containing, some one, some two, and some even four "red corpuscles," and these nearly as large as the free "red corpuscles" of the animal. REMAK, in like manner, speaks of one or more "red corpuscles" being formed within the colourless ones. Such appearances I have never observed.

† It appears almost unnecessary to remark, that this view of the nature of the "red corpuscle" of the fully-formed blood of Man and the Mammifera, completely sets aside the vexed question of a nucleus.

in a more or less marked manner two principal stages, a coarsely and a finely granular stage. In all the animals examined we likewise find blood-corpuscles in what I call the second phase of development, or phase of nucleated cell; this again presenting two principal stages, an uncoloured and a coloured. In *Branchiostoma lubricum* alone of all the oviparous Vertebrata, we have seen reason to conjecture (par. 20.) that the nucleated blood-cell occurs in the uncoloured stage only, or if a coloured stage exists, that the coloration is only in a very slight degree.

99. In regard to the nucleated blood-cell in the coloured stage, it is to be observed that it occurs in its highest degree of development and in great number only in the oviparous Vertebrata, in which it constitutes the "red corpuscle," and in the early mammiferous embryo. In the fully-formed blood of the Mammifera it occurs in a comparatively low degree of development, and in very small number.

100. It is in the Mammifera alone that we find the blood-corpuscle in what I call the third phase of development, or phase of free cellæform nucleus*. This exists in both uncoloured and coloured stages. In the former stage it is rare, in the latter it is the "red corpuscle" of the fully-formed blood of Man and the Mammifera. In the early mammiferous embryos which I have examined there have always been, in addition to the numerous "red corpuscles" similar to those of the oviparous Vertebrata, *i. e.* red nucleated blood-cells, some "red corpuscles" similar to those of the fully-formed mammiferous blood. Is there a period in the development of the mammiferous embryo when there exist in the blood no such "red corpuscles," viz. free cellæform nuclei in the coloured stage?

The summary now given will be found both tabularly and pictorially illustrated by the Plate.

PART II.

In this part of my subject, I purpose to examine the corpuscle of the lymph of vertebrate animals, and to compare it with the corpuscle of their blood.

The Corpuscle of the Lymph of the Skate and Mackerel.

101. The lymph of the Skate examined was obtained from the orbit in very small quantity, and could not be considered a good specimen. The corpuscles were besides a few granule-cells, nucleated cells in the uncoloured stage,—the cell-wall of many extremely pale,—and some nucleated cells in the earlier stage of coloration,—all identical with the corresponding corpuscles of the blood of the animal. (See figs. 1 to 6.)

102. The lymph of the Mackerel, taken as an example of an osseous fish, was likewise obtained from the orbit, and might be viewed as a good specimen. It contained granule-cells, nucleated cells in the uncoloured stage,—many with the cell-wall so pale as to be readily overlooked without attentive examination,—and nucleated cells

* Free nuclei, which may be met with in the blood of oviparous Vertebrata, are to be looked upon as mere abortions of a third phase of the blood-corpuscle.

in the earlier part of the stage of coloration,—all identical with the corresponding corpuscles of the blood of the animal.

The Corpuscle of the Lymph of the Frog.

103. The lymph subjected to examination was obtained from one of the posterior lymph hearts. The corpuscles were,—1st. Corpuscles at once recognisable as identical with the granule-cells of the blood of the animal, and these in both coarsely and finely granular stages. There were also cells in transition from granule to nucleated cells. 2nd. Corpuscles which at first sight appeared to be free nuclei, but were discovered on closer examination to be inclosed within cells of a circular or oval form, and extremely pale. The identity of these cells with the nucleated cells, uncoloured stage, of the blood of the animal could not be overlooked. 3rd. A considerable number of red nucleated cells, the same as the “red corpuscles” of the blood. Many of these no doubt were derived from small blood-vessels which had been cut in opening the lymph heart, but some of them I am inclined to believe belonged to the contents of the lymph heart, those especially which appeared to be in an early stage of coloration. (See the figures of the blood of the Frog.)

The Corpuscle of the Lymph of the Common Fowl.

104. The lymph subjected to examination was obtained from a lymphatic gland. It contained,—1st. Corpuscles about $\frac{1}{3000}$ th of an inch in diameter, less or more, identical with the granule-cells of the blood of the same animal; some being in coarsely and some in finely granular stages (figs. 1 to 2.). 2nd. Corpuscles in much greater number than the preceding, of the form of circular discs, with a depressed point in the centre about $\frac{1}{7000}$ th of an inch in diameter, and though colourless very distinct. At first glance these corpuscles appeared to be free, but subjected to more careful examination, they were observed to be contained within a cell of a diameter of about $\frac{1}{3000}$ th of an inch, the wall of which was extremely pale. Having once perceived it, however, there was no difficulty in recognising the whole as a nucleated cell identical with the nucleated cell of the blood of the animal, in its uncoloured stage (fig. 3.). There were some nucleated cells similar to those just noticed, but slightly tinged red in the interior; and besides such there were some oval nucleated cells, altogether similar to the oval red corpuscles of the blood of the animal, but coloured only, and that slightly in the interior, the circumferential doubling of the cell-wall appearing quite transparent and colourless.

The Corpuscle of the Lymph of Man and the Mammifera.

105. The description of the corpuscles of the lymph, here to be given, was drawn from the examination of those presented by the contents of the thoracic duct. Besides the contents of the thoracic duct of the human subject, I have also particularly examined the contents of the thoracic duct of the Rabbit, and found their corpuscles to be in all essential respects identical.

106. The corpuscles were,—1st. Granule-cells in both coarsely and finely granular stages, altogether similar to those of the blood (figs. 1, 2.). 2nd. Besides many cells in transition from granule to nucleated phase, nucleated cells in both uncoloured and coloured stages, quite the same as those of the blood (figs. 7 and 15 *a.*). The nucleated cells were fully distended independent of the addition of water, and were comparatively the most numerous of the corpuscles in the lymph; those in the coloured stage being more so than those in the uncoloured stage. Slight as the coloration of the coloured stage of the nucleated cell was generally, some few cells presented it perhaps in a more marked manner than is usually presented by the same cells as they occur in the fully-formed blood; in this respect approaching to the red nucleated cell of the blood of the early mammiferous embryo. Some even were of an oval shape. 3rd. A considerable number of free cellæform nuclei, both uncoloured and in different degrees of progressive coloration. These free cellæform nuclei were not much affected by the action of acetic acid or water. Lastly, there were seen here and there among the other corpuscles the empty shell of a nucleated cell in the coloured stage, with a free cellæform nucleus beside it as if just extruded by the bursting of the cell-wall. This is a circumstance which may be viewed as additional evidence, and this of a direct kind, in support of the view above given of the nature and origin of the “red corpuscle” of Man and the Mammifera.

107. From the account now given of the corpuscle of the lymph of vertebrate animals, it appears that it is identical with the corpuscle of their blood. In the oviparous Vertebrata, it occurs, like the corpuscle of their blood, in the two phases of granule and nucleated cell; whilst in Man and the Mammifera it occurs, like the corpuscle of their blood, in the three phases of granule-cell, nucleated cell and free cellæform nucleus.

108. The only difference that exists between the corpuscle in the lymph and the corpuscle in the blood, is, as regards the oviparous Vertebrata, the little degree of coloration which the coloured stage of nucleated cell as yet presents, and as regards the Mammifera, the small degree of coloration which the coloured stage of free cellæform nucleus has as yet attained.

109. The comparatively small total amount of corpuscles in the lymph is well-known. As regards the relative number in the different phases of the corpuscle, it is to be remarked that in the oviparous Vertebrata, the nucleated cells are, as in the blood, more numerous than the granule-cells. The nucleated cells are also more numerous than the granule-cells in the lymph of Man and the Mammifera, which is different from what obtains in their blood. Taking into account this relatively great number of nucleated cells, and the existence, though in less numbers, of free cellæform nuclei, we might compare the contents of the thoracic duct of a mammiferous animal, in respect both of the kinds of corpuscles and of their relative but not absolute numbers, with the blood of its early embryo state. The circumstances above-mentioned, that some of the nucleated cells of the contents of the thoracic duct present in the coloured

stage coloration in a pretty marked degree, and that some are of an oval shape, give additional exactness to the comparison*.

* In the descriptions which have been given by authors of the corpuscles of the lymph much confusion exists. An exposure of the principal causes of this may perhaps prove useful and instructive.

1st. Observations made on the corpuscles of the lymph of oviparous vertebrate animals have been adopted as applicable to the corpuscles of the lymph of Man and the Mammifera, whereas it will have been seen from what has been above said, that the corpuscles of the lymph of the oviparous Vertebrata can no more be taken as an exemplification of the corpuscles of the lymph of Man and the Mammifera, than the blood-corpuscles of the former as an exemplification of those of the latter.

2nd. HEWSON, it is known, gave the name of "central particles" to the nuclei of the red corpuscles of the blood of the oviparous Vertebrata. He at the same time supposed that he had seen similar particles in the interior of the red corpuscles of the blood of Man and the Mammifera.

Having observed in the juice of lymphatic glands, bodies which he supposed to be free, and which he recognised to be similar to the central particles of the red corpuscles of the blood, HEWSON came to the conclusion that the central particles are at first free, and that they subsequently become surrounded with the red coloured cell-wall, which he called "vesicular portion".

How HEWSON should have come to this conclusion is explicable, as regards the juice of the lymphatic glands of Birds, on the following supposition. In the juice of the lymphatic glands of Birds, it has been above seen, that nucleated cells in the uncoloured stage exist in great numbers; but that whilst the nucleus is very distinct, the cell-wall is extremely pale. In consequence of this HEWSON appears to have overlooked the cell-wall and distinguished the nucleus alone, but when the cell-wall had already become evident around the nucleus by having acquired colour, he naturally supposed that it was a new formation.

How HEWSON should have come to the same conclusion as regards the lymph of Man and the Mammifera, however, is scarcely explicable on any supposition. For to say nothing of the circumstance that there is not a "central particle" in the red corpuscle of the blood of the Mammifera, HEWSON'S description of "central particles" in the juice of the lymphatic glands of the Mammifera cannot apply to the cellæform nuclei of the uncoloured nucleated cells, seeing that the cellæform nucleus of the uncoloured nucleated cell is nearly, if not as large, as the perfect red corpuscle itself, which he alleged to contain the "central particle." The difficulty is still the same, even supposing HEWSON to refer to free cellæform nuclei in the uncoloured stage, and still greater supposing him to refer to granule-cells.

3rd. Since HEWSON'S time the cell-wall of the uncoloured nucleated cell in the lymph, especially of the oviparous Vertebrata, has continued to be generally overlooked, and the nucleus described as free. The nucleus moreover has been confounded with the granule-cell, which is what is commonly taken as the type of the "lymph-corpuscle." The same confusion prevails in regard to the lymph of Man and the Mammifera, with this additional complication, viz. that granule-cells have been confounded with free cellæform nuclei in the uncoloured stage.

WAGNER participating in the error of confounding granule-cells with cellæform nuclei, but having seen and distinguished the cell-wall of nucleated cells, he has taken their cellæform nucleus for a granule-cell, which had acquired a cell-wall around it.

Of all the authors I am acquainted with, HENLE alone has accurately distinguished the different forms of the corpuscle of the lymph of Man and the Mammifera, without however pointing out their relationship; but in his account of the corpuscles of the lymph of the Frog, he has fallen into inaccuracies similar to some of those which have been above pointed out.

¹ He believed, it may be further remarked, though not immediately to our present purpose, that the central particles were first formed in the lymphatic glands, and, after being received into the blood from the trunk of the lymphatic vessels, were in the course of the circulation carried to the spleen, where they acquired the red vesicular portion; and so the "red corpuscle" was formed. He believed also that the addition of the vesicular portion might likewise take place in the lymphatic glands.

EXPLANATION OF THE PLATE.

PLATE I.

LAMPREY.

Though it was not considered necessary to describe the blood-corpuscles of the Lamprey particularly, a few figures of them are given for the sake of comparison.

First Phase.—Granule-cell.

Fig. 1. Granule-cell somewhat distended by the action of water.

Second Phase.—Nucleated Cell.

Fig. 2. A blood-cell in a state of transition from the phase of granule-cell to that of nucleated cell.

Fig. 3. Nucleated cell, uncoloured stage.

Fig. 4 *a*. Nucleated cell, coloured stage.

Fig. 4 *b*. The same cell after the action of acetic acid, whereby the nucleus has been distinctly brought out.

SKATE.

First Phase.—Granule-cell.

Fig. 1. A granule-cell in the coarsely granular stage, presenting a clear spot on one side indicating the place of the nucleus.

Fig. 2 *a*. Granule-cell distended by the action of water.

Fig. 2 *b*. The same cell after the action of acetic acid. The granules have been dissolved and a cellæform nucleus brought into view.

Fig. 3. Granule-cell in the act of changing its shape, with movements of its granules, as described, par. 30 *et seq*.

Fig. 4 *a*. Granule-cell in the finely granular stage after the action of water.

Second Phase.—Nucleated Cell.

Fig. 4 *b*. A cell in transition from the phase of granule-cell to that of nucleated cell.

Fig. 5 *a*. Nucleated cell, uncoloured stage, circular.

Fig. 5 *b*. A similar cell collapsed.

Fig. 6. Nucleated cell in transition from the circular and uncoloured nucleated cell to the oval red nucleated cell, or nucleated cell in the second or coloured stage.

Fig. 7. The nucleated cell in the second or coloured stage.

FROG.

First Phase.—Granule-cell.

Fig. 1 *a*. Granule-cell in coarsely granular stage, and in the act of changing its shape (par. 59.).

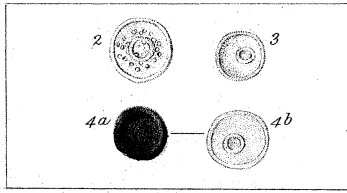
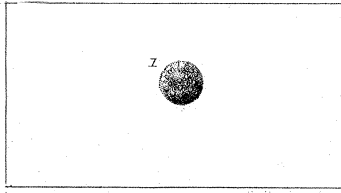
The Blood-corpuscle in its different Phases of development in Vertebrate Animals

1st Phase
Granule Cell.


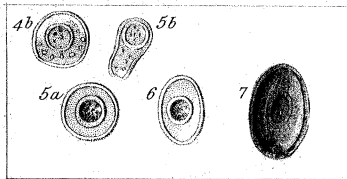
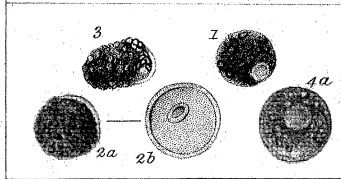
2nd Phase
Nucleated Cell.

3rd Phase
Free Cellæform Nucleus.


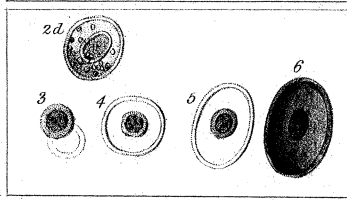
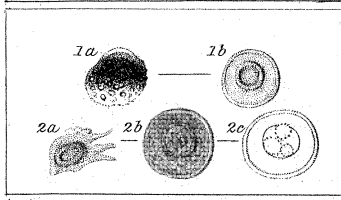
Lamprey.



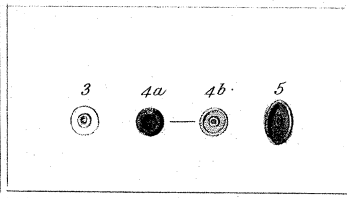
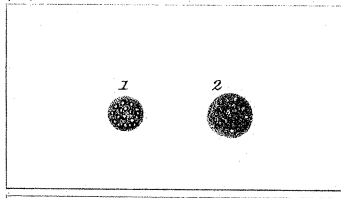
Shake.



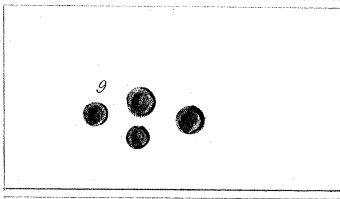
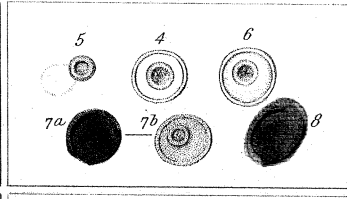
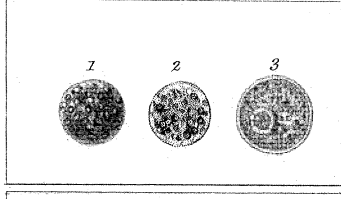
Frog.



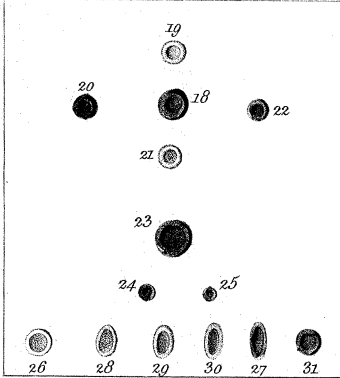
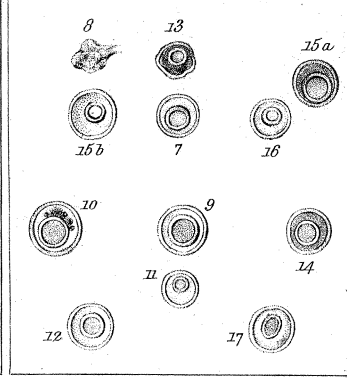

Common Fowl.



Man. Embryo.



Man and Mammifera.



Ad nat. del. Auctor.

J. Basire sc.

All the objects here represented are magnified 550 diameters.
The microscope a compound one by Ross.—the object glass $\frac{1}{8}$ inch.

- Fig. 1 *b*. The same cell after the action of acetic acid. The granules have been dissolved and a cellæform nucleus exposed.
- Fig. 2 *a*. Granule-cell in finely granular stage, after having collapsed and shot out processes.
- Fig. 2 *b*. The same, distended by water.
- Fig. 2 *c*. The same, after the action of acetic acid. If the acid has been very much diluted, and applied only after the distention of the cell by water, the appearance of the single large cellæform nucleus is produced; in the contrary case, the appearance of several small ones.

Second Phase.—Nucleated Cell.

- Fig. 2 *d*. Cell in transition from granule to nucleated phase.
- Fig. 3. Nucleated cell, uncoloured stage. The very pale cell-wall is seen on one side only of the very distinct nucleus.
- Figs. 4 and 5. Nucleated cells, uncoloured stage, the one circular and the other oval.
- Fig. 6. Nucleated cell, coloured stage, or the well-known oval "red corpuscle."

COMMON FOWL.

It has not been thought necessary particularly to describe the blood-corpuscles of the Bird. These few figures of the blood-corpuscle of the Common Fowl have been given merely for the sake of reference and comparison.

First Phase.—Granule-cell.

- Fig. 1. Granule-cell, coarsely granular stage.
- Fig. 2. Granule-cell, finely granular stage.

Second Phase.—Nucleated Cell.

- Fig. 3. Nucleated cell, uncoloured stage.
- Fig. 4 *a*. Nucleated cell, coloured stage, but still circular.
- Fig. 4 *b*. The same cell, with the nucleus brought into view by the action of acetic acid.
- Fig. 5. Nucleated cell, coloured stage, oval.

MAMMIFEROUS EMBRYO—Ox, $1\frac{1}{4}$ inch long.

First Phase.—Granule-cell.

- Fig. 1. Granule-cell, coarsely granular stage.
- Fig. 2. Granule-cell in transition from coarsely granular to
- Fig. 3. Finely granular stage. This cell, in which the cellæform nucleus is already visible through the finely granular contents, may be viewed as a transition to the phase of nucleated cell.

Second Phase.—Nucleated Cell.

- Fig. 4. Nucleated cell, uncoloured stage. The cell-wall, which is very pale, is seen all round the very distinct cellæform nucleus.
- Fig. 5. Nucleated cell, uncoloured stage. The cell-wall, which has just been brought out by distention with water, is extremely pale, and is seen only on one side of the very distinct cellæform nucleus.
- Fig. 6. A nucleated cell in transition to the coloured stage.
- Fig. 7 *a*. Nucleated cell, coloured stage, circular.
- Fig. 7 *b*. The same, after the action of acetic acid.
- Fig. 8. Nucleated cell, coloured stage, oval.

Third Phase.—Free Cellæform Nucleus.

- Fig. 9. Free cellæform nuclei, coloured stage, or “red corpuscles,” similar to those of the fully-formed blood of the animal.

MAN AND THE MAMMIFERA.

First Phase.—Granule-cell.

- Fig. 1 *a*. The granule-cell of human blood in its coarsely granular stage distended by water.
- Fig. 1 *b*. The same, after being acted on by acetic acid. The granules have been dissolved and a single cellæform nucleus disclosed.
- Fig. 2 *a*. The granule-cell of human blood in its finely granular stage in a state of collapse.
- Fig. 2 *b*. The same, distended by water.
- Fig. 3 *a*. The granule-cell, coarsely granular stage, of the blood of the Horse.
- Fig. 3 *b*. The same, after being acted on by acetic acid.
- Fig. 4. The granule-cell, finely granular stage, of the blood of the Horse.
- Fig. 5 *a*. The granule-cell, coarsely granular stage, of the blood of the Elephant.
- Fig. 5 *b*. The same, in process of being acted on by acetic acid.
- Fig. 6. The granule-cell, finely granular stage, of the blood of the Elephant.

Second Phase.—Nucleated Cell.

- Fig. 7. Nucleated cell of human blood, uncoloured stage, distended by water.
- Fig. 8. The same, in a state of collapse.
- Fig. 9. Nucleated cell of the blood of the Elephant in its uncoloured stage.
- Fig. 10. The same, in a state of transition from the granule-cell.
- Fig. 11. Nucleated cell, uncoloured stage, of the blood of the Goat.
- Fig. 12. Nucleated cell, uncoloured stage, of the blood of the Paco.
- Fig. 13. Nucleated cell, coloured stage, from the blood of the Horse.
- Fig. 14. Nucleated cell, coloured stage, from the blood of the Elephant.

Fig. 15 *a*. Coloured nucleated cell from human blood.

Fig. 15 *b*. Nucleated cell, in transition from uncoloured to coloured stage, from the blood of the Horse.

Fig. 16. Nucleated cell, in transition from uncoloured to coloured stage, from the blood of the Sheep.

Fig. 17. Nucleated cell, in transition from uncoloured to coloured stage, from the blood of the Paco.

Third Phase.—Free Cellæform Nucleus.

Fig. 18. Free cellæform nucleus, coloured stage, of human blood.

Fig. 19. Free cellæform nucleus, uncoloured stage, of the blood of the Horse.

Fig. 20. Free cellæform nucleus, coloured stage, of the blood of the Horse.

Fig. 21. Free cellæform nucleus, in transition from uncoloured to coloured stage, of the blood of the Horse.

Fig. 22. Free cellæform nucleus, coloured stage, of the blood of the Sheep.

Fig. 23. Free cellæform nucleus, coloured stage, of the blood of the Elephant.

Figs. 24 and 25. Free cellæform nuclei, coloured stage, of the blood of the Goat.

Fig. 26. Free cellæform nucleus, uncoloured and circular stage, of the blood of the Paco.

Fig. 27. Free cellæform nucleus, coloured and oval stage, of the blood of the Paco.

Figs. 28, 29, 30. Free cellæform nuclei, in transition from uncoloured and circular stage to coloured and oval stage, of the blood of the Paco.

Fig. 31. Free cellæform nucleus, coloured stage, of the blood of the Paco rendered circular by the action of water.

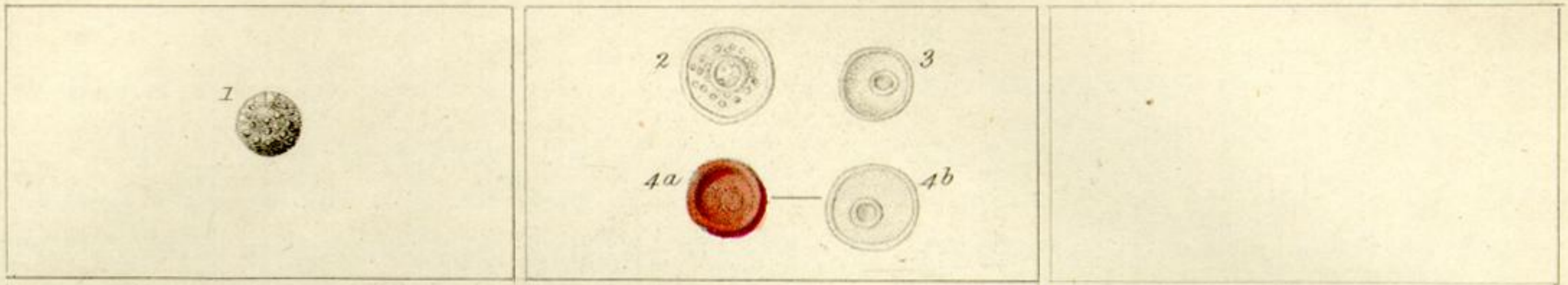
The Blood-corpuscle in its different Phases of development in Vertebrate Animals.

1st Phase
Granule Cell.

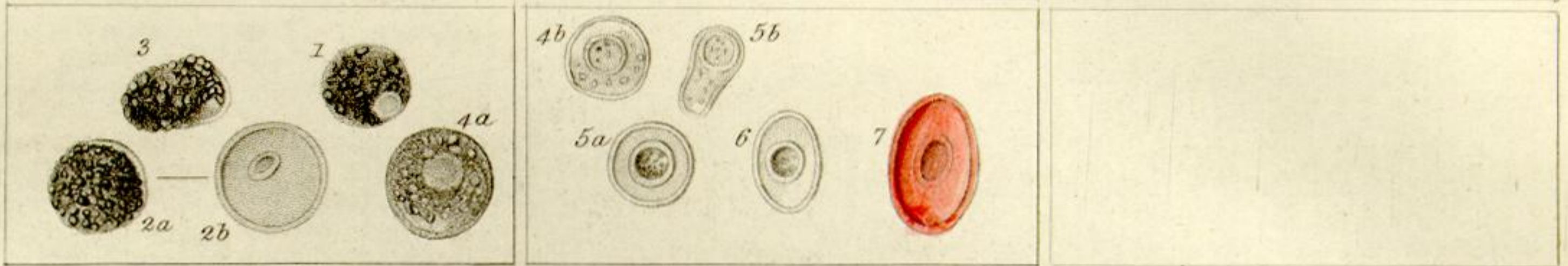
2nd Phase
Nucleated Cell.

3rd Phase
Free Cellular Nucleus.


Lamprey.



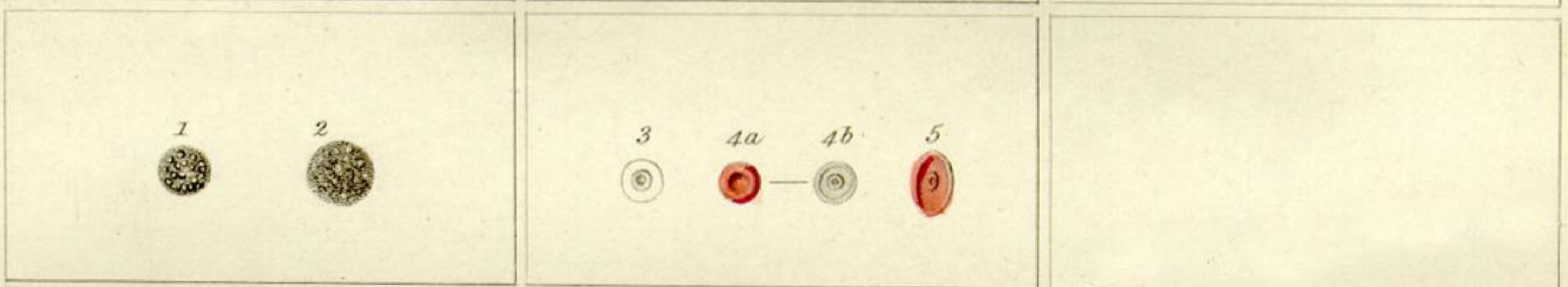
Skate.



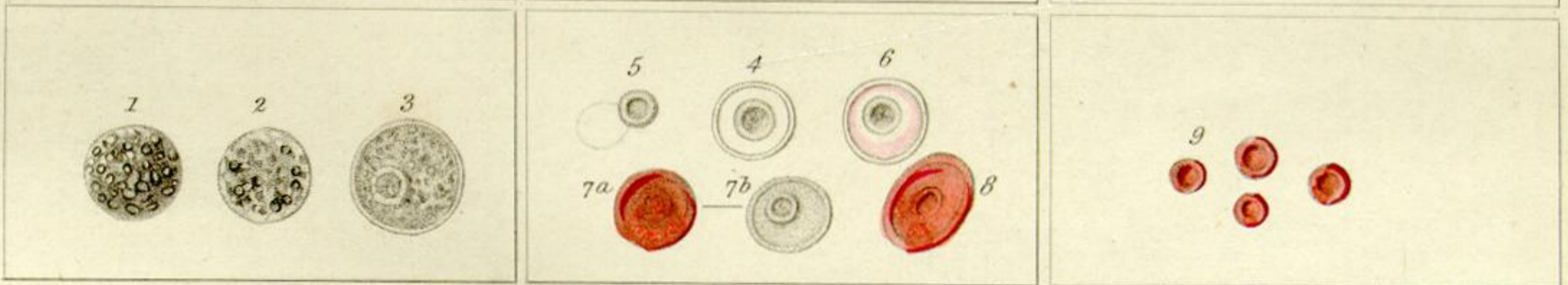
Frog.



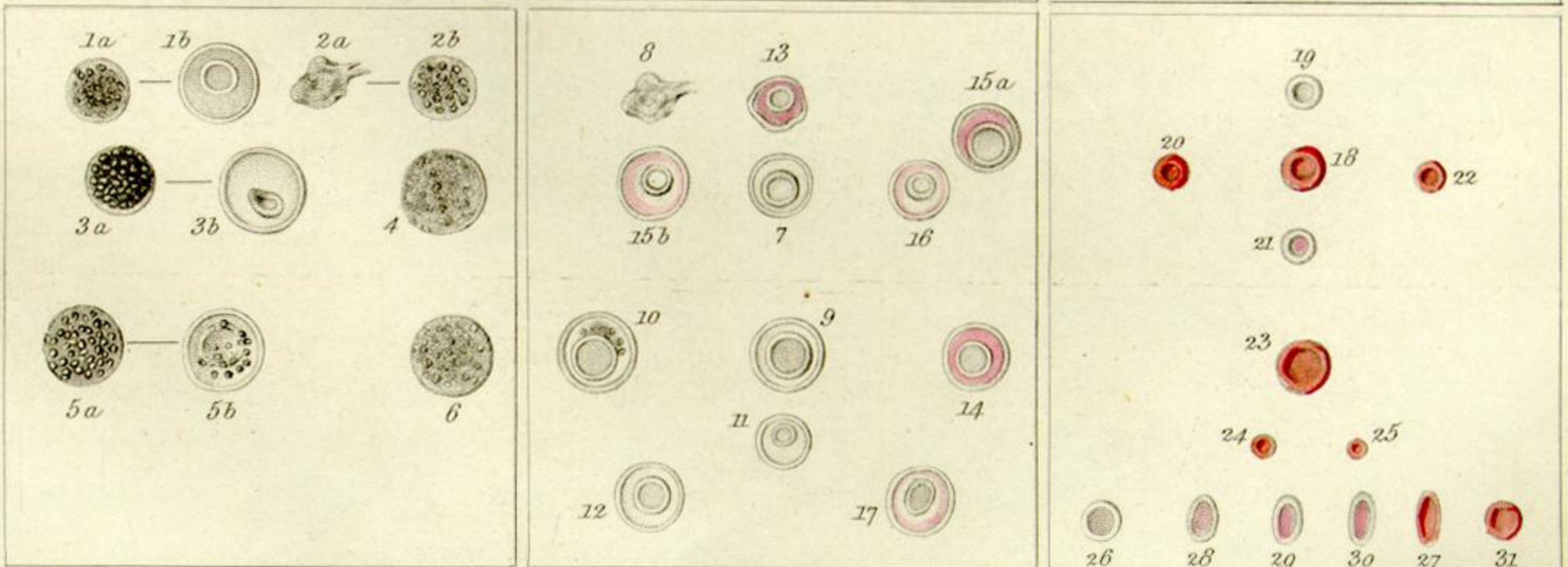
Common Fowl.



Mam. Embryo.



Man and Mammifera.



Ad nat. del. Auctor.

J. Basire sc.

All the objects here represented are magnified 550 diameters.
The microscope a compound one by Ross.—the object glass $\frac{1}{8}$ th inch.